

Ultrasound-guided Ankle Arthrocentesis



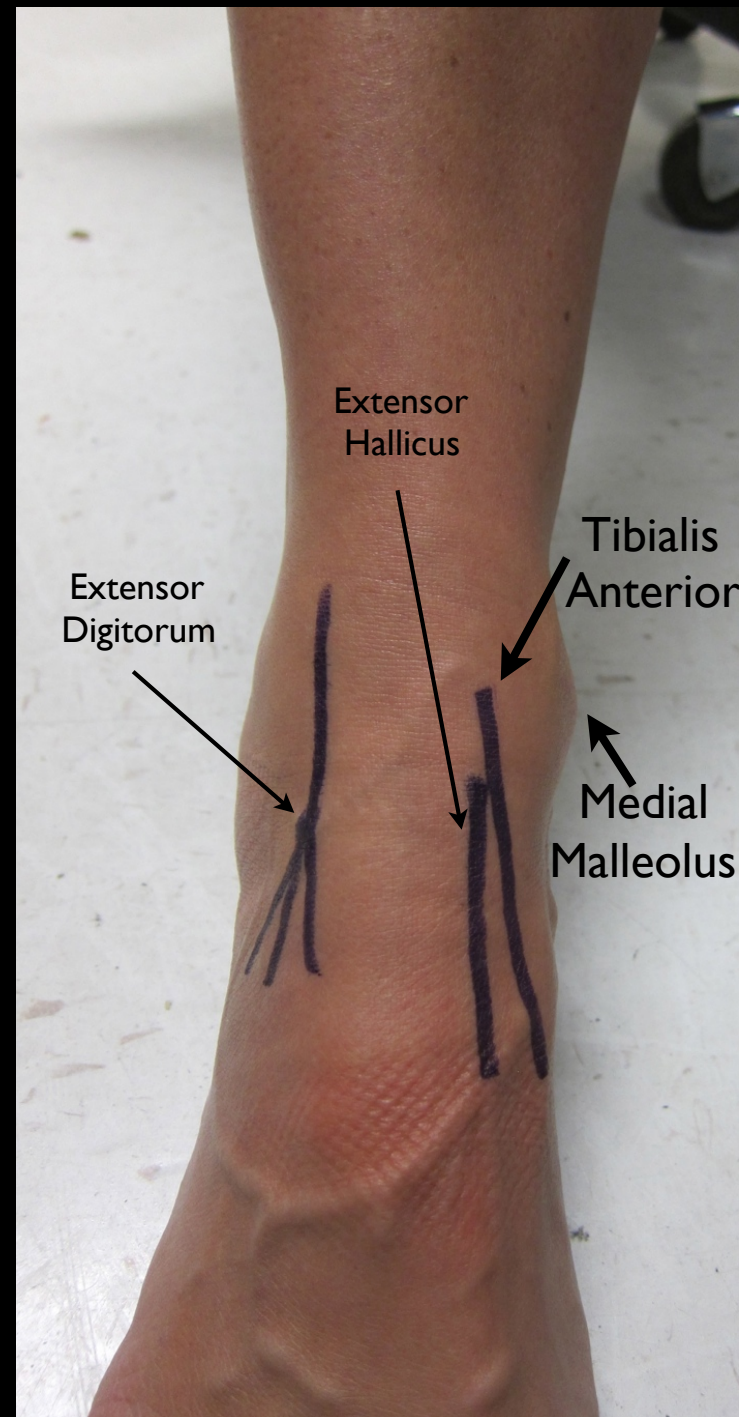
Arun Nagdev, MD
@NagdevArun

STEP 1

Identify pertinent palpable landmarks

- 1) Tibialis Anterior Tendon
- 2) Medial Malleolus

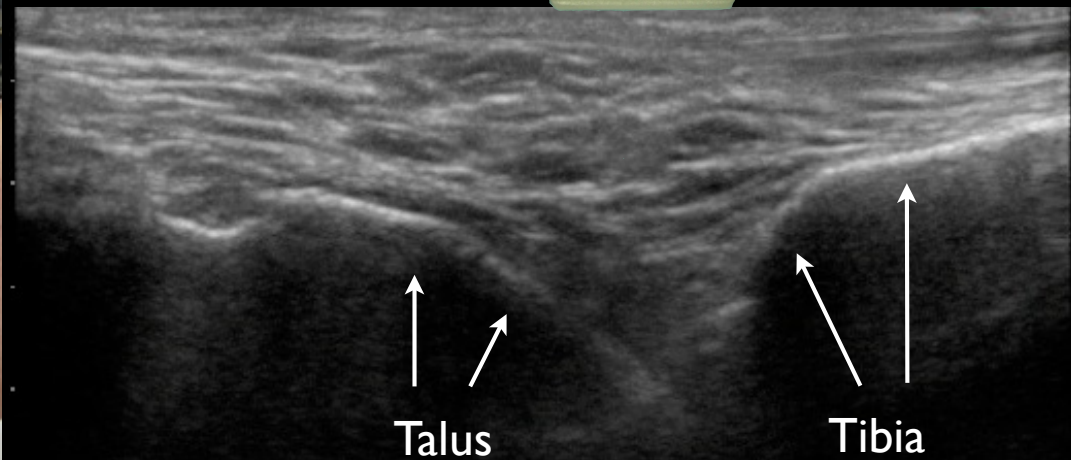
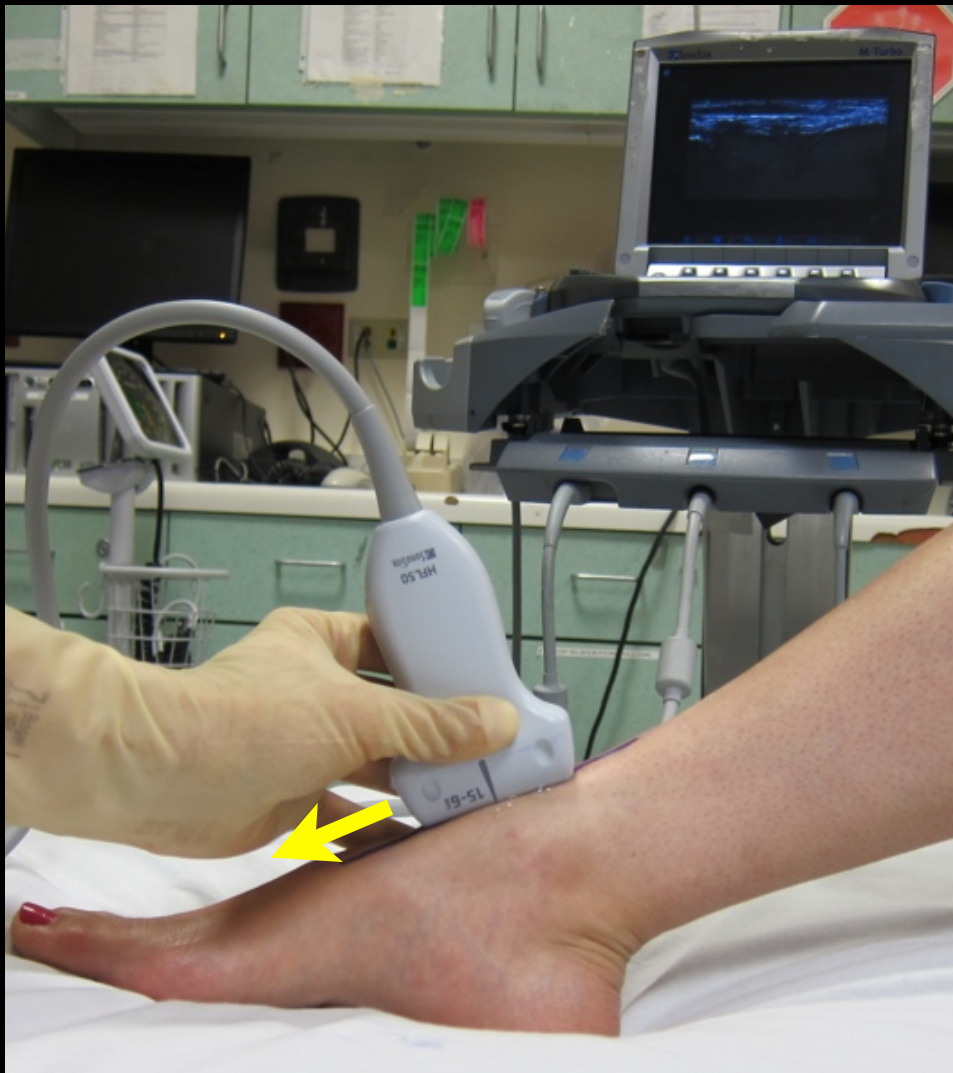
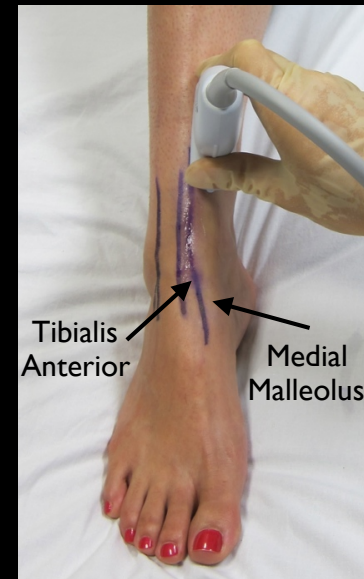
Lateral



Medial

STEP 2

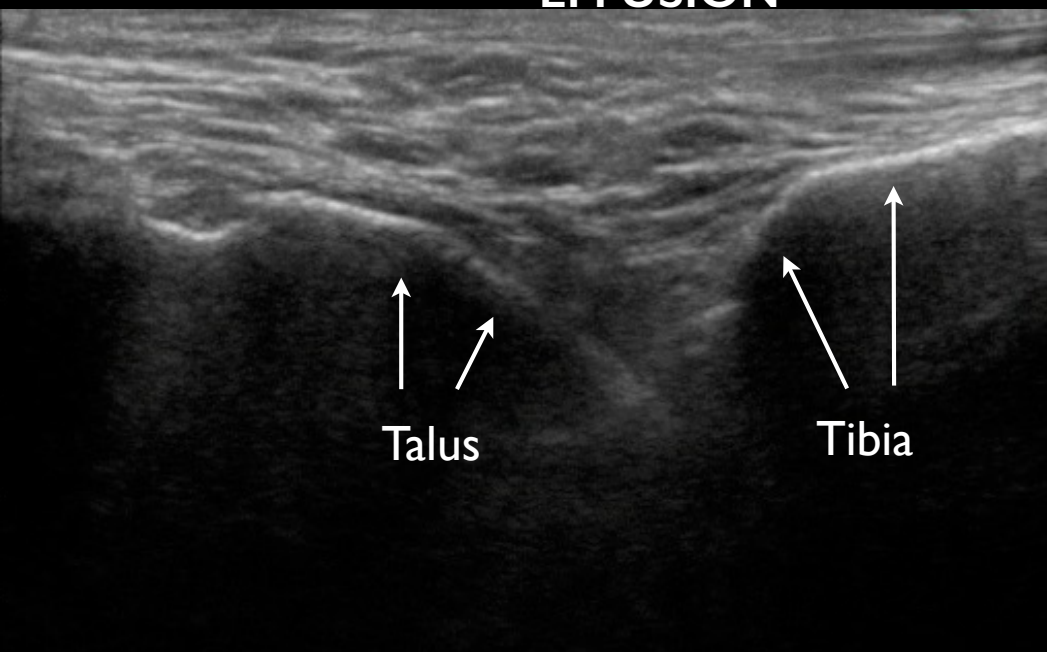
- 1) Linear Probe
- 2) Probe marker caudal (to the feet)
- 3) Identify Tibia with Ultrasound
- 4) Slide distal and identify joint space between Tibia and Talus



STEP 3

- 1) Identify the presence of an effusion
- 2) Move the probe slightly medial (in between Tibialis Anterior and Medial Malleolus)

**NO
EFFUSION**



EFFUSION

